



PROTECTIVE EFFECT OF MANDARIN (*CITRUS RETICULATA*) PEEL EXTRACT ON POTASSIUM DICHROMATE INDUCED HEPATOTOXICITY AND NEPHROTOXICITY IN RATS

Samir AE Bashandy¹, Abeer Salama¹, Abdel-Hameed M. Fayed¹, Enayat A. Omara²,
Sayed A. El-Toumy³ and Josline Y. Salib³.

¹Department of Pharmacology, Medical Division, National Research Centre,
33 EL Bohouth St. (former EL Tahir St.), Dokki, Cairo, Egypt. P.O.12622.

²Department of Pathology, Medical Division, National Research Centre,
33 EL Bohouth St. (former EL Tahir St.), Dokki, Cairo, Egypt. P.O.12622.

³Chemistry of Tannins Department, National Research Centre, Dokki, Cairo, Egypt.
33 EL Bohouth St. (former EL Tahir St.), Dokki, Cairo, Egypt. P.O.12622.

Abstract

The present study evaluate the ability of water extract of mandarin (*Citrus reticulata*) peel to mitigate the hepatorenal toxicity of potassium dichromate ($K_2Cr_2O_7$). Both doses of peel extract (200mg/Kg & 400mg/Kg) and $K_2Cr_2O_7$ (15mg/Kg) were orally administered to rats for eight weeks. Treatment of rats with mandarin peel extract along with $K_2Cr_2O_7$ led to a decrease in the activities of serum aspartate aminotransferase (AST), alanine aminotransferase (ALT) and gamma- glutamyl transferase (GGT) as well as reduction in the levels of creatinine, urea and uric acid. Moreover, the treatment with peel extract of mandarin relieved oxidative stress manifested by a decrease of malondialdehyde (MDA) levels with a significant elevation of antioxidant capacity (TAC), hepatorenal contents of superoxide dismutase (SOD) and reduced glutathione (GSH). The treatment with extract of mandarin peel displayed anti-inflammatory property as concluded from its lowering effect of serum tumor necrosis factor-alpha (TNF- α) level. Finally, the peel extract minimized the pathological changes in liver and kidney evoked by $K_2Cr_2O_7$ and the immune-histochemical study revealed that mandarin peel extract minimized the increase of hepatorenal activity of P53 compared to $K_2Cr_2O_7$ group. The peel extract of mandarin can efficiently alleviate the hepaorenal toxicity of $K_2Cr_2O_7$ via its antioxidant and anti-inflammatory properties.

Key words: Mandarin peel extract, potassium dichromate, hepatotoxicity, nephrotoxicity, rats.

Introduction

Chromium (Cr) is a heavy metal familiar in the environment and contaminates environmental systems since it is vastly used in diverse industrial processes (Bagchi *et al.*, 2002). Chromium compounds are used in paints, tanning of leather, manufacture of magnetic tape and as catalyst for hydrocarbons production (Sreeram and Ramasami, 2003; Weckhuysen and Schoonheydt, 1999). During metabolism of chromium, it is transformed to reactive chromium intermediates that produce reactive oxygen species (ROS) (O'Brien *et al.*, 2001). ROS can give rise to tissues injury, damage of cellular components and oxidative stress (Valko *et al.*, 2006; Yam-Canul *et al.*, 2008). On the other hand, chromium exists in different

states, being hexavalent chromium [Cr (VI)] and trivalent chromium [Cr (III)] the most stable forms. Cr (III) is predominantly present in the environment and in salts used as micronutrients and dietary supplements (Pechova and Pavlata, 2007). Cr (VI) salts such as potassium dichromate and chromic acid are widely used in leather, chrome-plating, and dye-producing industries (Bagashi *et al.*, 2002). Exposure to Cr (VI)-containing compounds is known to be toxic, mutagenic, and carcinogenic to human beings and diverse animals, leading to serious damage to the kidney, liver (Fathima and Priyanka, 2017) and other vital organs (Shrivastava *et al.*, 2002, Nudler *et al.*, 2002).

The scientist recommended in the use of natural

product that characterized by a huge source of remedies that control all of human kind insults, to avoid drugs toxicity the treatment of any insult of kidney or liver (the site of detoxification and toxicant elimination) (Abeer *et al.*, 2018). It has shown that natural antioxidant effect is the central role in effects associated with phytochemicals (Mohamed and Fayed, 2020).

Chromium given to rats led to increase of proteinuria, urea nitrogen and creatinine, as well as elevation in serum alanine aminotransferase activity and hepatic lipid peroxide production (Kim and Na 1991). Chromium has been reported to cause hepatotoxicity, nephrotoxicity and oxidative stress (Fathima and Priyanka 2017).

The genus *Citrus* of the family Rutaceae includes several important fruits such as oranges, mandarins, limes, lemons, and grapefruits. The citrus processing industry produces residues including peel from the extraction of citrus juice. The management of these wastes, which produce odor and soil pollution, represents the main problem for the food industry (Ma *et al.*, 1993). Citrus by-products, could be the important source of phenolic compounds. Citrus peel is a rich source of bioactive compounds including natural antioxidants such as phenolic acids and flavonoids (Li *et al.*, 2013). The peels of citrus fruit contain a higher amount of phenolics compared to the edible portions, the total phenolic compounds in the peels of lemons, oranges, and grapefruits were 15% higher than that of the pulp of these fruits (Gorinstein *et al.*, 2001).

The citrus peel contains glycosides, flavonoids, namely, hesperidin and naringin and polymethoxylated flavones (PMFs) such as nobiletin and tangeretin (Li *et al.*, 2014). It was postulated that PMFs showed antiobesity activity via reduction in the number of adipose cells due to apoptosis which aid in weight loss (Sergeev *et al.*, 2009). The bioactive compounds of the citrus peel are strongly associated with therapeutic properties including antiatherogenic, anticarcinogenic, anti-inflammatory and cardioprotective effects (Benavente-García and Castillo, 2008; Han *et al.*, 2012; Assini *et al.*, 2013). Many of these pharmacological activities of citrus polyphenols are resulted from their abilities to scavenge ROS and reactive nitrogen species (Mojzer *et al.*, 2016).

Mandarin peel extracts (MPE) showed antibacterial (Jayaprakasha *et al.*, 2000), antioxidant (Ferreira *et al.*, 2018) and neuroprotective activities (El-Khadragy *et al.*, 2014). Citrus peels ethanolic extracts can be used as anti-hepato-nephrotoxic agents against paracetamol-induced liver and kidney injuries (Mostafa *et al.*, 2016).

The aim of the present study is the alleviation effects of mandarin peel extract (MPE) on $K_2Cr_2O_7$ - induced hepatic and renal injuries in rats were investigated. In addition, the antioxidant and anti-inflammatory properties of peel extract in hepatorenal damage of potassium dichromate (PDC) model were studied.

Materials and Methods

Chemicals

Potassium dichromate was purchased from Sigma Aldrich, USA.

AST, ALT, GGT, creatinine, urea and uric acid kit, Saluca Company, Netherlands.

Total antioxidant capacity (TAC), (Bio Vesion Incorporated, USA,).

MDA, GSH and SOD kits of Biodiagnostic, Egypt.

Tumor necrosis factor (TNF- α), Elabscience ELIZA kits, USA

Vectastain Elite ABC Kit; Vector Laboratories, Burlingame, CA

Mandarin peel extract

Citrus reticulata is cultivated in the most gardens of all Egyptian governorates especially Upper Egypt (Assuit), delta (Mansoura), The fruits of *Citrus reticulata* were collected from Mansoura, Dakahlia, Egypt. During December 2015 – February 2016. It was authenticated by a plant taxonomist and a specimen (C_16) was stored in the National Research Centre Herbarium. These extracts were obtained by the following steps: Grinding of the fresh fruits peel (1kg) by the blender, Soaking this blender output in a sterile distilled water, warming at 40°C, filtration (using Whatmann No. 1 filter paper), separation by filtration and concentration on rotavapour (Buchi, USA) and then drying in lyophilizer (Labconco, USA) under reduced pressure, repeat extraction by using the fine particles of sediment to resoak in a sterile distilled water and repeat several times till obtaining clear supernatant the water extract was condensed by rotary evaporator then it was drying in Lyophilization to give a dry residue (350 g). Then this extract will be stored in an airtight container in a refrigerator below 10°C.

Animals

Forty adult male Wistar albino rats, weighing between 150-200 g were obtained from the animal house colony, National Research Centre, Giza, Egypt. All animals were kept in metal cages at animal house of National Research Centre, Giza under standard conditions. Food and water were available to the rats. All experiments were carried out according to the ethical guidelines for care and use

of experimental animals approved by the Ethical Committee of the National Research Centre. The Ethical approval under (15170-3/6).

Experimental design

Animals were randomly divided into five groups, each of eight animals. Group 1: control (daily received only 5ml/kg saline for two months, orally), Group 2: Rats daily received mandarin peel extract (MPE) at dose of 400mg/kg for two months, orally, Group 3: Rats received daily $K_2Cr_2O_7$ (PDC) at dose level of 15mg/kg (Salama *et al.*, 2014), orally for two months. Groups 4 & 5: Rats were given two different oral doses 200mg/kg and 400mg/kg concurrent with $K_2Cr_2O_7$, for two months respectively.

Blood collection and tissue preparation

Blood samples were collected from the retro-orbital venous plexus of rats under light ether anesthesia and collected in clean test tubes, allowed to clot, then centrifuged for 10 minutes at 3000 r.p.m. Serum was separated and stored into eppendorff tubes at $-20^\circ C$ to be used for determination of liver function parameters. After collection of blood samples, rats were sacrificed by cervical dislocation and their both kidneys and livers were immediately removed.

Biochemical analysis of serum samples

AST, ALT, GGT, creatinine, urea and uric acid were determined using kits produced by Saluca Company,

Netherlands. MDA was evaluated colorimetrically using kits purchased from Biodiagnostic, Egypt. Total antioxidant capacity (TAC) was assayed colorimetrically (Bio Vesion Incorporated, USA,).

Hepatic and renal oxidative stress parameters

Hepatic and renal MDA, GSH and SOD were determined colorimetrically using kits of Biodiagnostic, Egypt. Tumor necrosis factor (TNF- α) was evaluated in liver and kidney tissues using Elabscience ELIZA kits (USA).

Histopathological examination

Liver and kidney sections from all groups were fixed in 10% formalin, embedded in paraffin, and dehydrated in ascending concentrations of ethyl alcohol (70–100%). Subsequently, 5- μm tissue sections were cut, mounted on slides, stained with hematoxylin and eosin (H & E) for histopathological investigation.

Immunohistochemistry of p 53

Liver and kidney paraffin blocks were cut into 5 μm sections and mounted on positively charged slides for p53 immunohistochemistry. Sections were deparaffinized in xylene and rehydrated. The sections were incubated with Primary monoclonal antibody for p53 (code no: M7001, DAKO) at a dilution of 1 : 200, for 2 h at $25^\circ C$ in a humidification chamber. The slides were washed three times for 3 min. each with phosphate buffer saline (PBS).

Table 1: Effect of mandarin peel extract on liver and kidney functions of potassium dichromate (PDC) - induced hepatorenal toxicity in rats.

	Control	High dose MPE.	PDC	PDC+ Low dose MPE.	PDC+High dose MPE.
AST(U/L)	49.60±0.61	55.67±3.86	77.20±1.86 ^a	54.20±4.73 ^b	47.00±1.02 ^b
ALT(U/L)	33.32±0.72	25.78±1.04	58.30±0.99 ^a	36.64±0.69 ^b	35.6±0.59 ^b
GGT(U/L)	35.47±2.03	40.13±3.47	112.65±6.10 ^a	70.70±6.25 ^{ab}	40.80±7.02 ^b
Creatinine(mg/dl)	1.21±0.10	1.10±0.16	2.08±0.03 ^a	1.98±0.25 ^a	1.58±0.01 ^{ab}
Urea (g/dl)	42.34±1.07	50.63±4.81	56.96±0.40 ^a	53.82±0.85 ^a	48.09±2.47 ^b
Uric acid(mg/dl)	3.89±0.14	3.64±0.22	8.43±0.32	6.55±0.26 ^{ab}	4.00±0.18 ^b

Values represent the mean ± S.E. n=8

a = P < 0.05: Statistically significant from control group.

b = P < 0.05: Statistically significant from K₂Cr₂O₇ group by using ANOVA and LSD

Table 2: Effect of mandarin peel extract on hepatic and renal oxidative stress parameters of potassium dichromate (PDC) treated rats

Group/Organ	Parameter	Control	high dose MPE	PDC	PDC+ Low dose MPE	PDC+high dose MPE
liver	GSH(mg/g tissue)	9.83±0.53	11.29±0.62	6.18 ±0.29 ^a	6.85±0.11 ^{ab}	7.69±0.38 ^{ab}
	SOD(U/G tissue)	280.52±14.93	268.00±14.55	200.67±8.59 ^a	230.07±9.43 ^{ab}	270.06±18.00 ^b
Kidney	GSH(mg/g tissue)	7.48±0.20	8.04±0.79	3.09±0.06	4.89±0.19 ^{ab}	5.93±0.27 ^{ab}
	SOD(U/G tissue)	200.00±11.46	220.54±15.63	104.72±12.00	160.81±5.66 ^{ab}	210.24±17.86 ^b

Values represent the mean ± S.E. n=8

a = P < 0.05: Statistically significant from control group.

b = P < 0.05: Statistically significant from K₂Cr₂O₇ group by using ANOVA and LSD.

Biotinylated polyvalent secondary antibody (Vectastain Elite ABC Kit; Vector Laboratories, Burlingame, CA) was applied to tissue sections and co-incubated for 30 min. The reaction was visualized by Metal Enhanced DAB Substrate. Counterstaining was performed by adding an adequate amount of hematoxylin stain to the slide to cover the entire tissue surface. Slides were examined with the light microscope (Olympus BX-50 Olympus Corporation, Tokyo, Japan).

Statistical analysis

In the present study, all results were expressed as mean \pm standard error of the mean (SEM). Data analysis was achieved by one-way analysis of variance (ANOVA) followed by LSD (least significance difference) comparison test using GraphPad Prism software (version 5.00). The difference was considered significant when $P < 0.05$.

Results

Liver and kidney functions

The treatment of rats with $K_2Cr_2O_7$ elevated serum levels of AST, ALT, GGT, creatinine, urea and uric acid significantly as compared to control group (Table 1). No

significant difference was observed between control and $K_2Cr_2O_7$ + peel extract (200 or 400 mg/kg) in AST and ALT activities. The concentration of GGT, creatinine, urea and uric acid were significantly higher in $K_2Cr_2O_7$ + 200 mg/kg peel extract group than those of control, while they were not changed significantly in of $K_2Cr_2O_7$ + 400 mg/kg peel extract group except serum creatinine level. The administration of $K_2Cr_2O_7$ + 400 mg/kg peel extract exhibited a significant decrease of AST, ALT, GGT, creatinine, urea and uric acid serum levels significantly as compared to $K_2Cr_2O_7$ group. Also, the same results were recorded in $K_2Cr_2O_7$ + 200 mg/kg peel extract group relative to $K_2Cr_2O_7$ group except for serum creatinine and urea levels.

Oxidative stress parameters

A significant elevation of MDA level of $K_2Cr_2O_7$ group was observed in serum (Fig. 1) and in hepatic and renal tissues (Table 2). Also, the treatment with $K_2Cr_2O_7$ displayed a significant rise of hepatic and renal TNF- α level (Fig. 2). On the other hand, the administration of $K_2Cr_2O_7$ to rats led to a significant decrease of serum TAC (Fig. 1) and GSH or SOD contents of liver and kidney tissues (Table 2). The administration mandarin

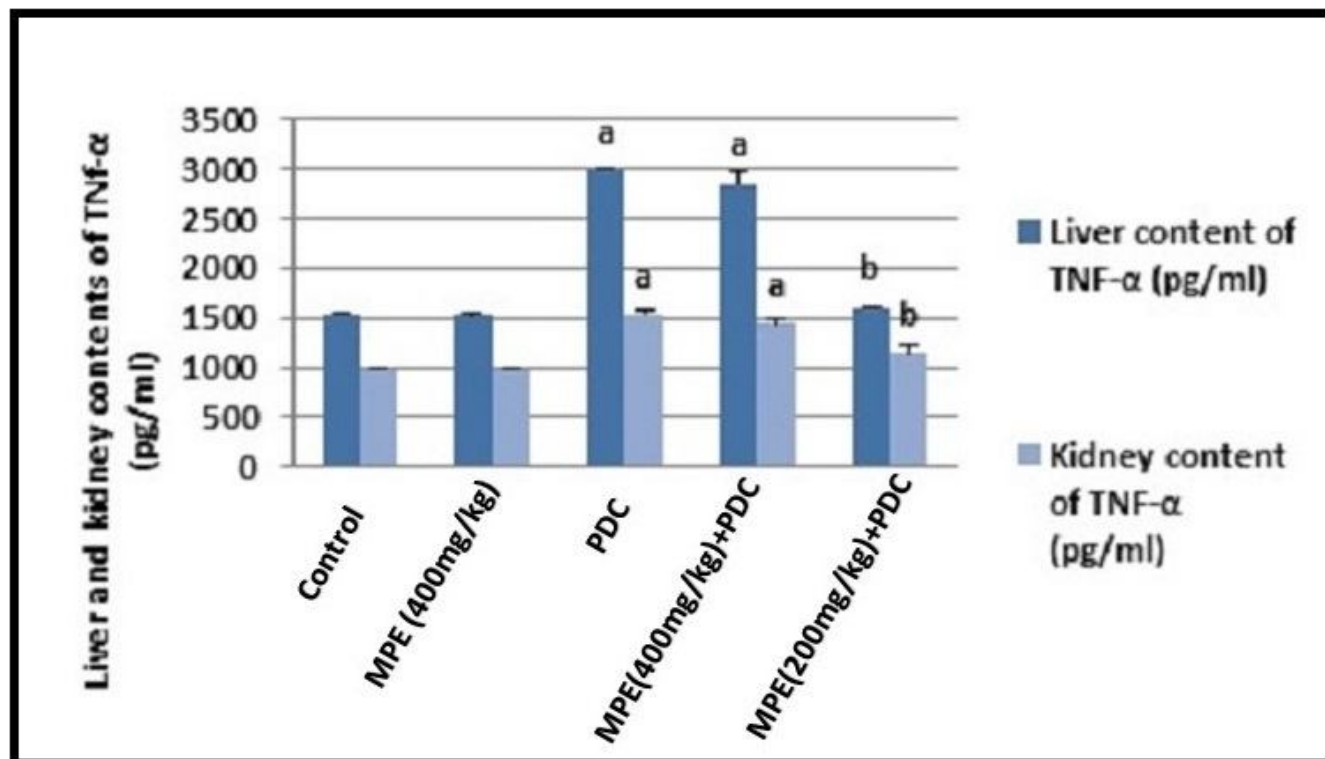


Figure 1: Effect of mandalime peel extract on Liver and kidney contents of TNF- α in potassium dichromate ($K_2Cr_2O_7$) - induced hepatorenal toxicity in rats.

Values represent the mean \pm S.E. n=8

a = $P < 0.05$: Statistically significant from control group.

b = $P < 0.05$: Statistically significant from $K_2Cr_2O_7$ group by using ANOVA and LSD

peel extract (200mg or 400mg/kg) + $K_2Cr_2O_7$ reduced the levels of MDA in serum or in liver and kidney tissues. Moreover, the treatment of mandarin peel extract (200mg or 400mg/kg) led to a significant increase of serum TAC and tissues GSH or SOD concentrations as compared with $K_2Cr_2O_7$ group. Treatment with mandarin in a high dose only (400 mg/kg) along with $K_2Cr_2O_7$ significantly reduced liver and kidney contents of $TNF-\alpha$ by 46 and 25% respectively as compared with $K_2Cr_2O_7$ group (Fig. 2).

Histopathological results

Liver

The hepatic tissues of the control or mandarin peel extract group had normal architecture (Fig. 3A and C). Liver of $K_2Cr_2O_7$ -administered rat had remarkable damage, including distortion of hepatic cells, focal necrosis, congestion of blood vessels, increased lymphocytic infiltration around central vein and portal tract. Also, pyknotic and apoptotic nuclei with proliferation of Kupffer cells was also noticed (Fig. 3B).

The liver sections of the rats administered $K_2Cr_2O_7$

and extract at low dose (200mg/kg) showed a sign of healing which was indicated the decrease of necrosis with mild inflammatory cell, pyknotic, apoptotic nuclei and activated Kupffer cells (Fig. 3D). These histopathological changes were reduced in livers of the potassium dichromate and extract at high dose(400mg/kg) group because the hepatocytes appeared with a normal pattern and the radial arrangement around the central vein was restored, although inflammatory cell and activated Kupffer cells were still found (Fig. 3E).

Kidney

The kidney sections of control and rats given peel extract only showed normal histological structures of glomeruli and renal tubules (Fig. 4A and C). The kidney section of potassium dichromate-treated rats showed variable and severe histopathological alterations in the form of degenerative changes. Glomeruli showed shrunken glomerular, thickening of glomerular basement membrane with focal periglomerular lymphocytic cell infiltration. Almost proximal and distal convoluted tubules revealed severe necrobiotic changes varying from diffuse

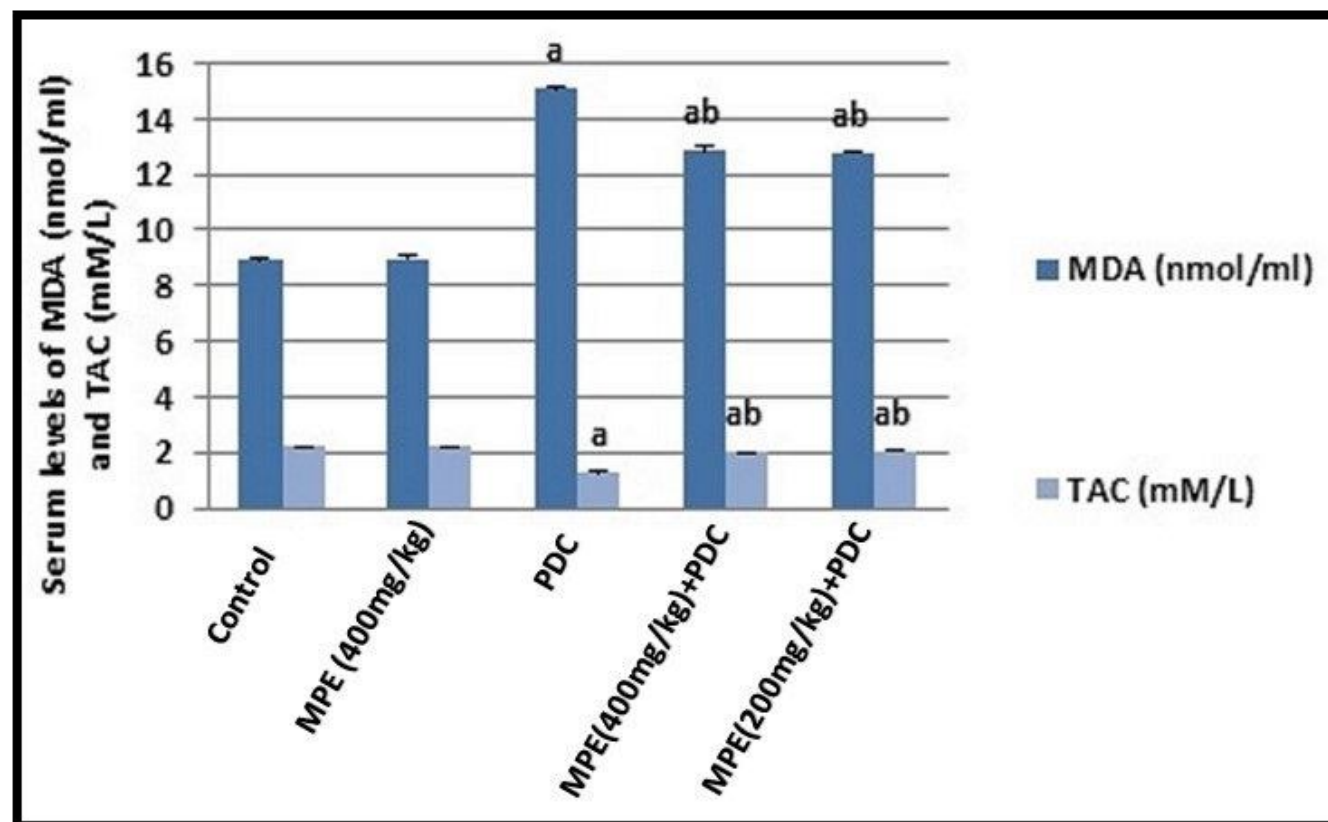


Figure 2: Effect of mandarine peel extract on Serum levels of MDA (nmol/ml) and TAC (mM/L) of potassium dichromate ($K_2Cr_2O_7$) - induced hepatorenal toxicity in rats.

Values represent the mean \pm S.E. n=8

a = $P < 0.05$: Statistically significant from control group.

b = $P < 0.05$: Statistically significant from $K_2Cr_2O_7$ group by using ANOVA and LSD

vacuolar degeneration to coagulative necrosis of their epithelial lining with pyknotic nuclei; intraluminal aggregation of renal cast and interstitial hemorrhage (Fig. 4B).

These pathological alterations were alleviated in rats given low dose of extract as renal tubules showed mild tubular damage with degeneration of their epithelial lining and very mild inflammatory cell infiltrates in addition to few regenerative renal tubules (Fig. 4D). On the other

hand, Kidney section of rats treated with a high dose of peel extract + potassium dichromate showed marked improvements compared to $K_2Cr_2O_7$ treated one, with a minimal inflammatory reaction, and moderate tubular damage characterized by focal necrosis of epithelial lining associated (Fig. 4E).

Immunohistochemical results

Most of the hepatocytes in the control and rats given mandarin peel extract only appeared negative immuno-

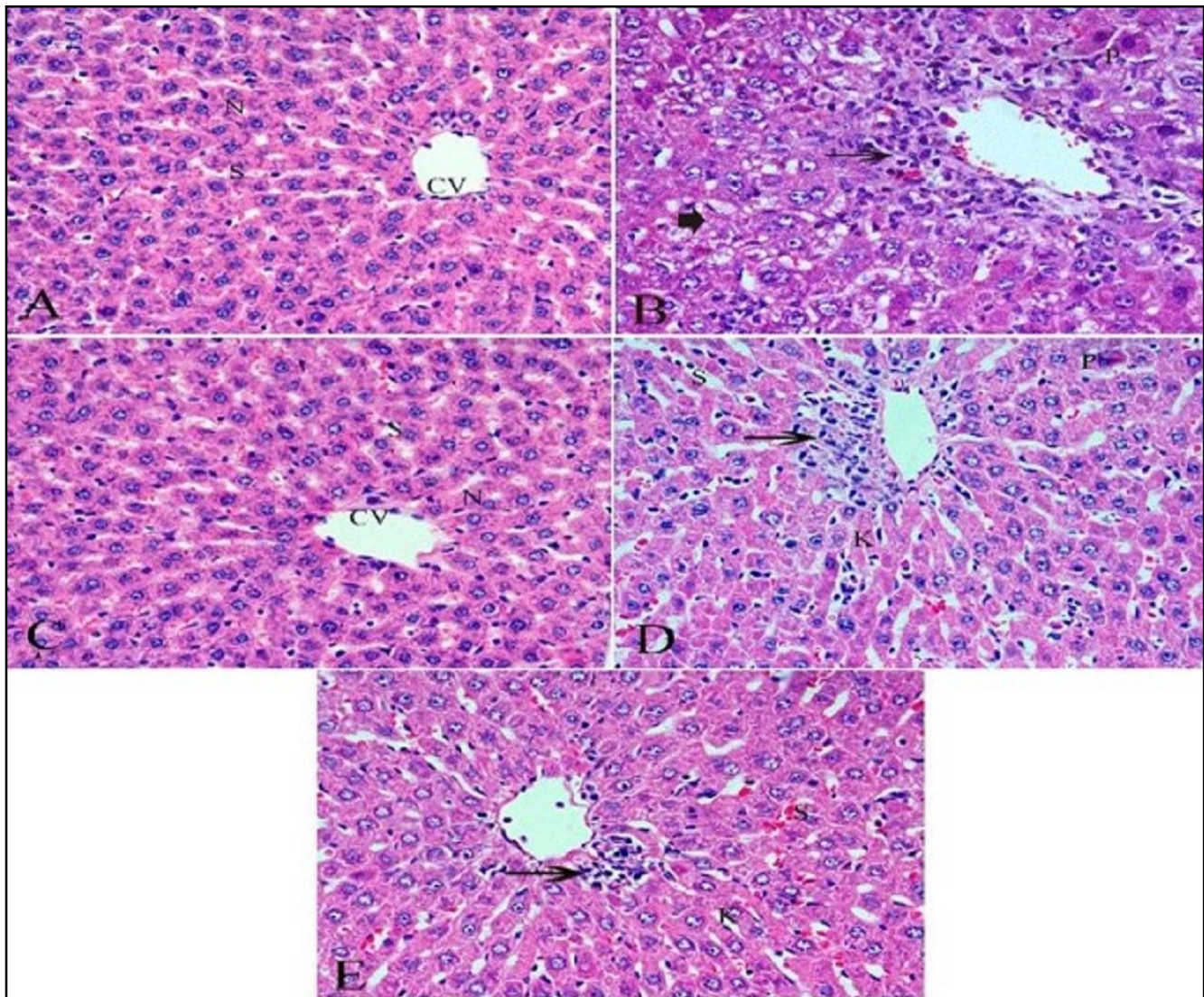


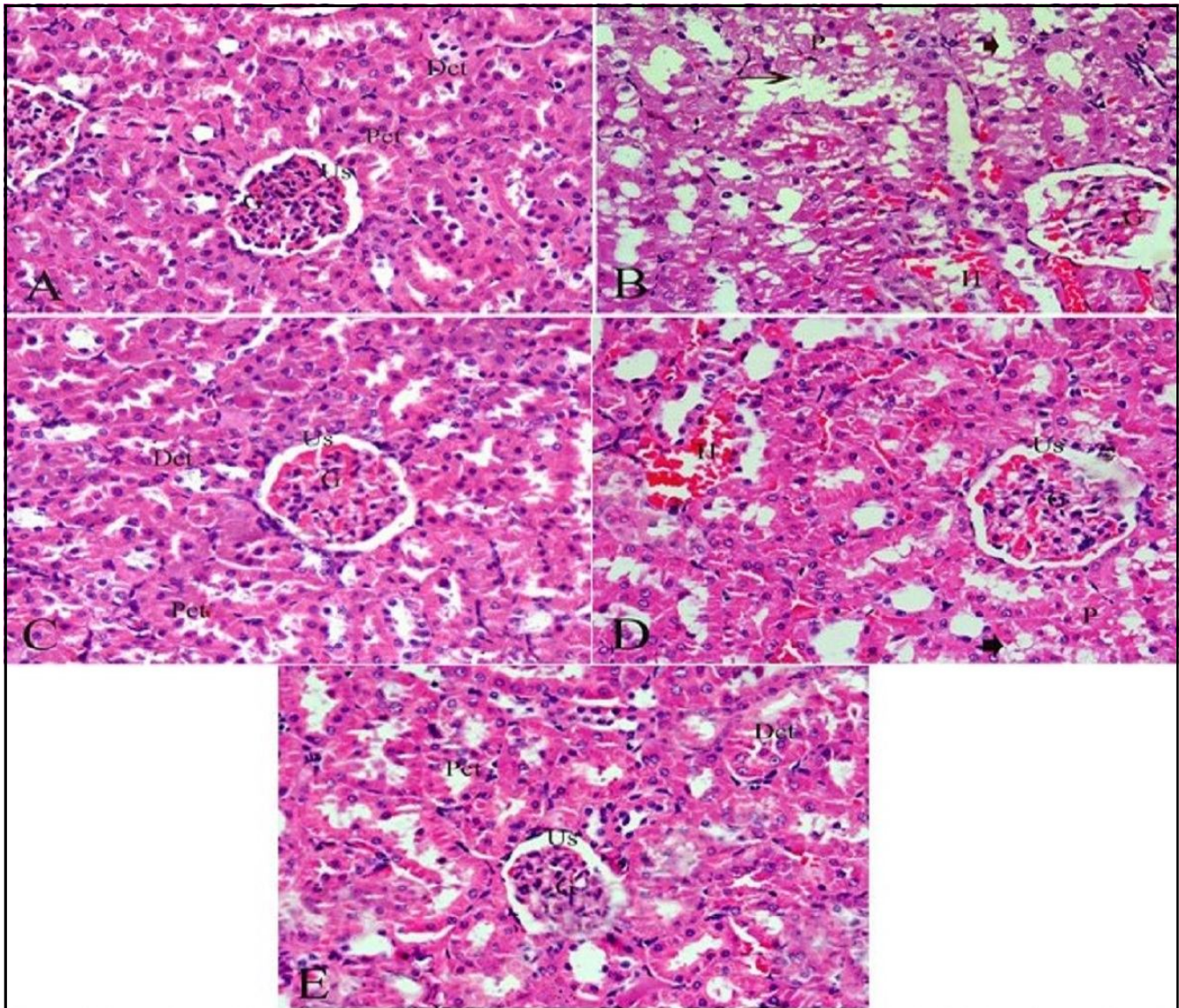
Figure 3: Photomicrographs of sections of the liver tissue stained with hematoxylin and eosin (H & E):

- A. Control group showed normal hepatic architecture, central vein (CV), hepatic cells with, blood sinusoid (S) and nucleus (N).
- B. Potassium dichromate treated group showing distortion of hepatic cells necrosis (arrow head), increased lymphocytic infiltration around central vein (thin arrow), pyknotic nuclei (P).
- C. Plant extracts group showing normal hepatic architecture
- D. Potassium dichromate and plant extract (low dose) group showing mild inflammatory cell (thin arrow) and pyknotic (P) and activated Kupffer cells (K)
- E. Potassium dichromate and plant extract (high dose) group, showing normal pattern of liver cells and activated Kupffer

staining reactions for p53 (Fig. 5A and C). $K_2Cr_2O_7$ treated group revealed intensity brown color in the cytoplasm of most liver cells (Fig. 5B). The rats administered peel extract of both two doses along with $K_2Cr_2O_7$ showed reduction in the p53 activity in the hepatocytes to be more or less similar to the control group in dose depended manner (Fig. 5D and E).

The results of the immunohistochemical assessment

of P 53 immunoreactive cells in the kidney tissues showed no immune reaction was demonstrated in control and peel extract group (Fig. 6A and C). Diffuse intensely stained glomerular and renal tubular epithelial cells were demonstrated in the $K_2Cr_2O_7$ treated group (Fig. 6B). On the other hand, color intensity was greatly reduced in the potassium dichromate and mandarin peel extract (low and high dose) group in a dose-dependent manner (Fig. 6

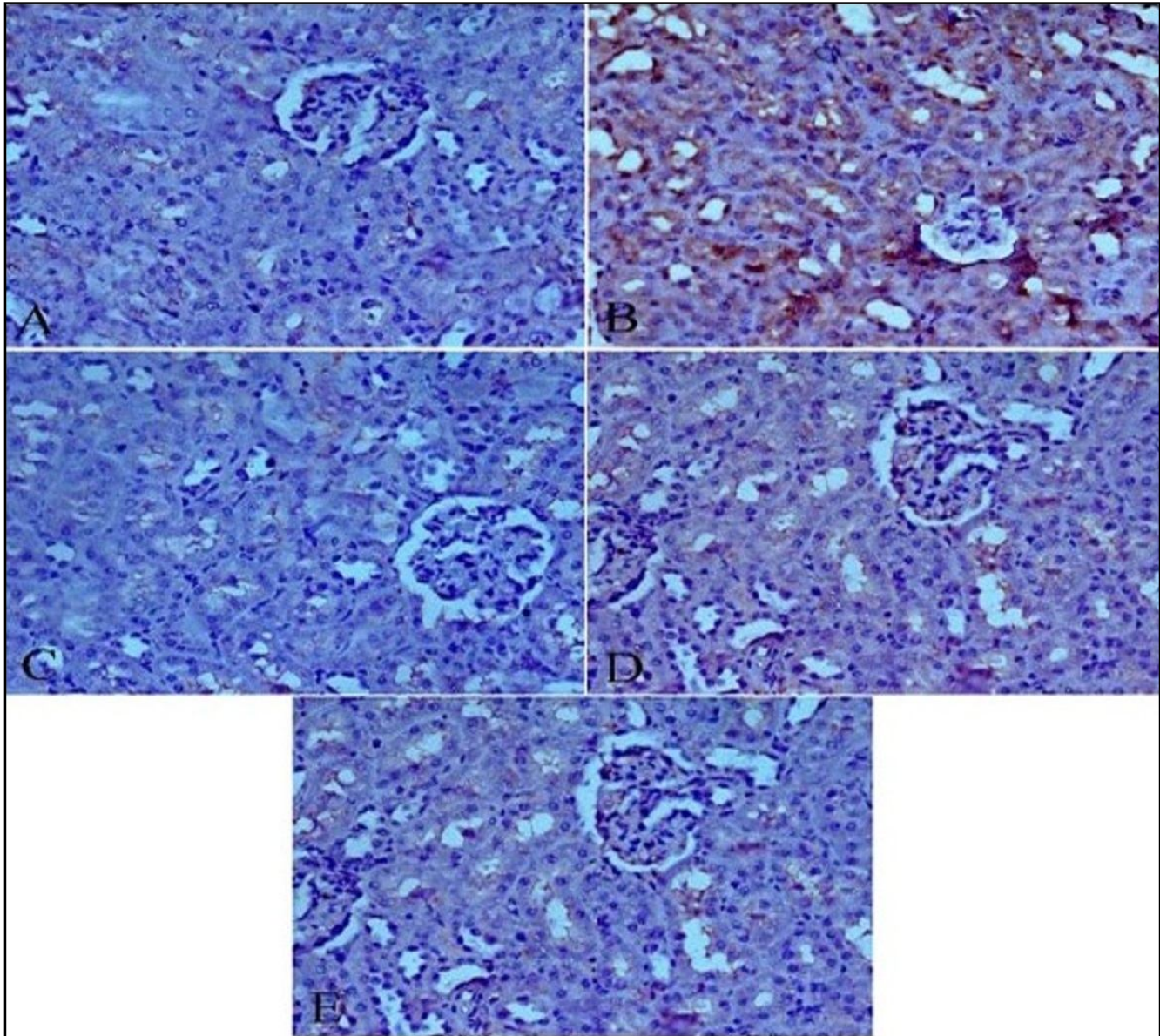


Figure_4: Photomicrographs of sections of the kidney tissue stained with hematoxylin and eosin (H & E).A. Control group showed normal glomerulus (G) surrounded by Bowman's capsule (Urinary space US), proximal (Pct) and distal (Dct) convoluted tubules. B. Potassium dichromate treated group showing shrunken and degeneration glomerular (G), proximal convoluted tubules revealed severe necrosis of their epithelial lining (thin arrow), vacuolar degeneration (arrow head), with pyknotic nuclei (P) and interstitial heamorrhaghe (H) C. Plant extract group showing nearly normal structure D. Potassium dichromate and plant extract low dose showing mild glomerular damage (G), mild wide urinary space (US), tubular degeneration of their epithelail lining (arrow head) with pyknotic nuclei (P) and interstitial heamorrhaghe (H) E. Potassium dichromate and plant extract high dose group, showing nearly normal structure with mild wide urinary space (US) (H & E $\times 400$).

D and E).

This study was designed to check the protective effect of mandarin peel extract on hepatorenal toxicity of $K_2Cr_2O_7$ encouraged alteration of liver and kidney functions. In our study, the treatment of rats with $K_2Cr_2O_7$ produced a significant increase of both hepatic (AST, ALT & GGT) and renal (Creatinine, Urea and Uric acid)

function markers suggesting pathological changes of these organs. Renal damage evoked by $K_2Cr_2O_7$ has been previously linked with oxidative stress (Salama *et al.*, 2016), acute necrosis of renal tubules (Reddy *et al.*, 2015) and tubular epithelial hyperplasia and apoptosis (Hegazy *et al.*, 2016). Also, oxidative stress is responsible for hepatotoxicity of $K_2Cr_2O_7$ (Navya *et al.*, 2018). Here,



Figure_5: Photomicrographs of sections of the liver tissue stained with P53 immunohistochemical stain

A. Control group showing no immune reaction was demonstrated of P 53

B. Potassium dichromate treated group showing strongly-stained of P 53 in the hepatic cells

C. Plant extracts showing no reaction of P 53

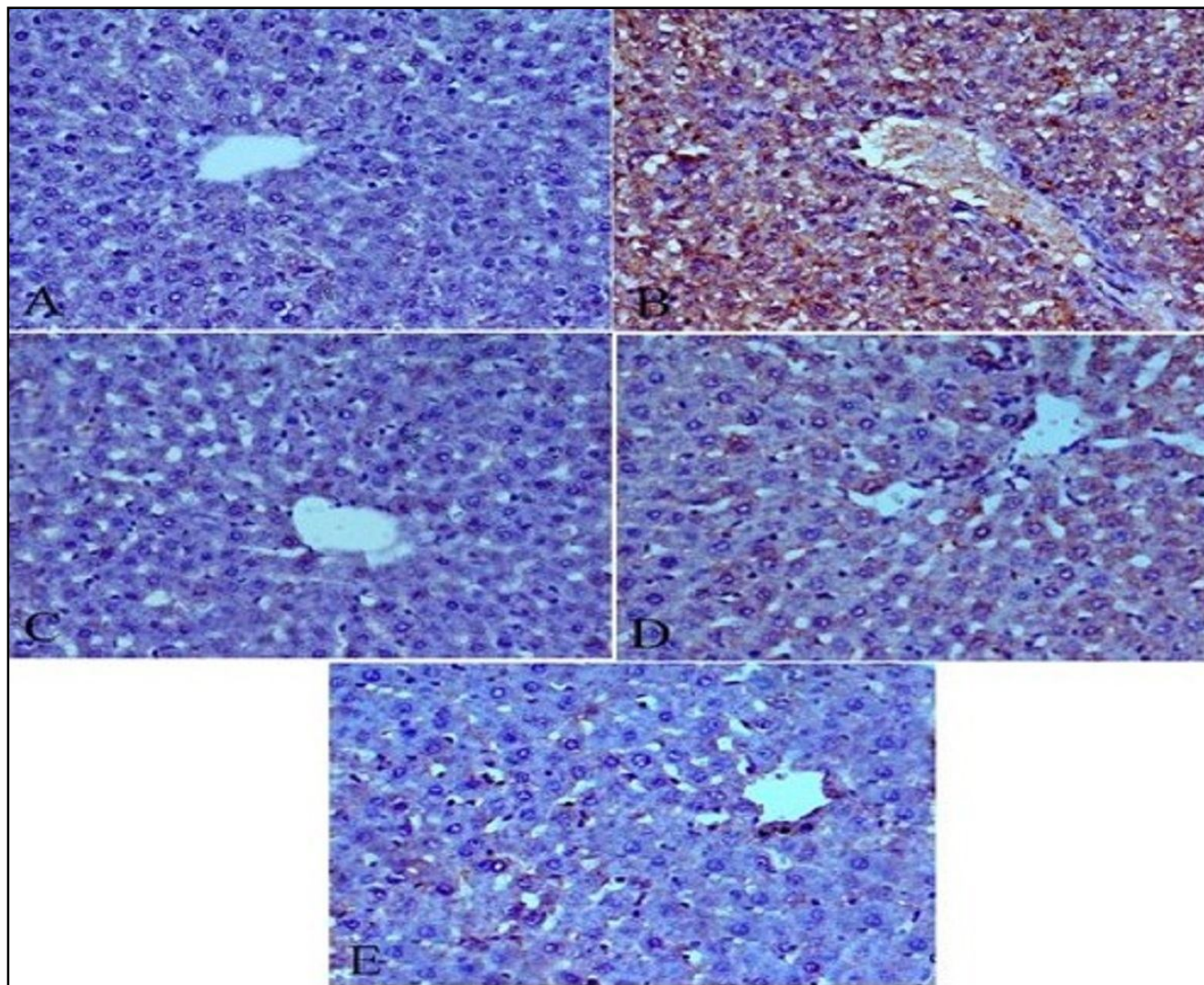
D. Potassium dichromate and plant extract low dose showing moderate intensity of immunostaining P 53

E. Potassium dichromate and plant extract high dose group showing slight intensity of immunostaining P 53

(Immunohistochemistry P 53, X 400).

the administration of $K_2Cr_2O_7$ only to rats resulted in a significant rise of MDA level in serum or hepatic and renal tissues. On the other hand, hepatic or renal GSH and SOD levels of $K_2Cr_2O_7$ group declined significantly. It appeared that ROS are involved in chromium provoked cell injury and cancer (Son *et al.*, 2013). MDA is one of the stable aldehydic products of LPO (Mylonas and Kouretas 1999). The toxicity of LPO products in

mammals comprises hepatotoxicity and nephrotoxicity (Boveris *et al.*, 2008). GSH is a tripeptide responsible for protection against ROS and detoxification of endogenous or exogenous toxins—SOD is an important endogenous antioxidant enzyme that eliminates and decomposes two molecules of superoxide anion to hydrogen peroxide (H_2O_2) and molecular oxygen (Halliwell and Gutteridge, 2007). All the pathological



Figure_6: Photomicrographs of sections of the kidney tissue stained with P53 immunohistochemical stain

A. Control group showing no immune reaction of P 53

B. Potassium dichromate treated group showing diffuse intensely stained glomerular and renal tubular epithelial cells of P 53

C. plant treated Potassium dichromate and plant extract, showing mild

D. Potassium dichromate and plant extract low dose showing reduced intensely stained of P 53

E. Potassium dichromate and plant extract high dose group, showing marked reduced intensely stained of P 53 (Immunohistochemistry P 53, X 400).

changes observed in liver and kidney of rats treated with $K_2Cr_2O_7$ can be referred to an increase of MDA and a decrease of SOD or GSH levels that indicated a rise of oxidative stress in these organs.

Also (Mohamed and Fayed, 2020) reported that the reduction of oxidative process stimulated and deactivated specific genes that confirmed many secondary stages in disease circumstance so the choice of Mandarin peel that presented the highest antioxidant capacity that correlated with bioactive compounds and minerals (Barros *et al.*, 2012). Here, it appeared that mandarin peel extract decreases the oxidative stress as suggested from the improvement of liver or kidney marker tests (AST, ALT, GGT, Creatinine, Urea and Uric acid), pathological changes, SOD and GSH levels. The decline of MDA levels and the increase of antioxidant capacity due to the treatment of rats with mandarin peel extract may explain the reduction in the pathological changes result from $K_2Cr_2O_7$. The bioactive compounds in the mandarin peel extract as flavonoids, phenolics and steroids (Justin *et al.*, 2014) may play a vital role in the amendment of hepatorenal function and antioxidant defense system. The protective effects of flavonoids in biological systems are attributed to their efficiency to inhibit oxidative stress and LPO (Zielinska *et al.*, 2001). It was suggested that the antioxidant properties of hesperidin (A flavonoid of mandarin peel) that scavenge free radicals might be the main factor responsible for protective action on CCl_4 -induced hepatotoxicity (Abdel Halim *et al.*, 2017) and prevent the toxic effects of gentamicin evoked nephrotoxicity (Anandan and Subramanian, 2012).

During inflammation, many cytokines are upregulated and accumulated in the liver; among them, TNF- α has been implicated as a critical mediator of renal toxicity (Ghosh *et al.*, 2010) and hepatic injury (Gressner, 2001). In the current study, oral administration of peel extract to rats given $K_2Cr_2O_7$ produced a significant decrease in serum TNF- α level which may indicate anti-inflammatory properties of the extract. Flavonoids of citrus peel have been shown to reduce TNF- α levels through suppressing the expression of inducible NO synthase and cyclooxygenase-2 (Ha *et al.*, 2012). The relationship between oxidative stress and TNF- α is complicated and it has been shown that TNF- α increases ROS and ROS increases TNF- α level (Kuhad and Chopra, 2009).

Chronic hepatic injury is associated with both liver cirrhosis and liver cancer (Huang *et al.*, 2014). Several cytokines and ROS, generated in the injured liver tissue during inflammatory conditions, because changing of the hepatic stellate cells; into the activated phenotype, which

is accountable for fibrosis, cirrhosis and cancer (Gressner, 2001). Here, the administration of $K_2Cr_2O_7$ to rats led to significant increase in GGT level and enhancement in hepatorenal expression of P53 as demonstrated from immune-histochemical stain. Higher serum levels of GGT, within the normal range, are linked with an increased cancer risk (Strasak *et al.*, 2008). It was reported a rise in p53 expression in primary breast cancer (Angelopoulou *et al.*, 2000). The pattern of GGT and P53 of rats given 400mg/Kg peel extract + $K_2Cr_2O_7$ is nearly like the control. The peel extract of mandarin contains flavonoids as hesperidin that has shown promising results in the suppression of cancer (Stanisic *et al.*, 2018). Hesperidin possesses free radical scavenging, antioxidant and anti-inflammatory properties. It showed a potential chemopreventive activity against benzo(a)pyrene-induced lung cancer (Bodduluru *et al.*, 2015) or nitrosamine induced urinary bladder carcinogenesis (Yang *et al.*, 1997). It is appeared that mandarin peel extract lessened the deleterious effect of $K_2Cr_2O_7$ promoted liver and kidney toxicity along with oxidative stress.

Conclusion

Our current study demonstrates the protective effects of mandarin peel extract against $K_2Cr_2O_7$ -induced hepatorenal toxicity in rats as assured by biochemical assays and histopathological evaluation. The results of the present study suggest that peel extract of mandarin may exert its hepatorenal protective effect via its antioxidant and anti-inflammatory activities as manifested from decreasing MDA levels and TNF- α concentration and elevating antioxidant enzymes or antioxidant capacity. The implied mechanisms for this protective effect may be through various active constituents of the peel. Thus, preventing the oxidative stress pathway may be of therapeutic value in treatment of liver and kidney injuries. These findings led us to assumed that this extract may display a new prophylactic policy for reducing $K_2Cr_2O_7$ -induced hepatorenal damage. These results suggest that mandarin peel –supplemented diets should be added to diet style to develop a new therapeutic strategy for treatment of oxidative stress associated diseases.

References

- Abdel Halim ABT, N.M. Nur, E.S. El- Agamy and A. Ibrahim (2017). Protective Effect of Hesperidin (HDN) on Carbon Tetrachloride (CCl_4) - Induced Hepatic Toxicity in Male Albino Rats. *International Journal of Contemporary Research and Review*, **8(11)**: 20328-20338.
- Abeer, A.A.S., M.F. Abdel-Hameed, T.A. Attia *et al.*, (2018). Protective effects of moringa oleifera extract on isoniazid and rifampicin induced hepatotoxicity in rats: involvement

- of adiponectin and tumor necrosis factor- α . *Egypt J. Vet. Sci.*, **49**: 25-34. DOI: 10.21608/ejvs.2349.1025.
- Anandan, R. and P. Subramanian (2012). Renal protective effect of hesperidin on gentamicin-induced acute nephrotoxicity in male Wistar albino rats *Redox Report*, **17**(5): 219-26. doi: 10.1179/1351000212Y.0000000019. Epub Aug 9.
- Angelopoulou K., H. Yu, B. Bharaj, M. Gai and E.P. Diamandis (2000). p53 Gene Mutation, Tumor p53 Protein Overexpression and Serum p53 Autoantibody Generation in Patients with Breast Cancer. *Clinical Biochemistry*, **33**(1): 53-62.
- Assini, J.M., E.E. Mulvihill, B.G. Sutherland *et al.*, (2013). Naringenin prevents cholesterol-induced systemic inflammation, metabolic dysregulation and atherosclerosis in Ldlr-/- mice. *Journal of Lipid Research*, **54**(3): 711-724.
- Bagchi, D., S.J. Stohs, B.W. Downs, M. Bagchi and H.G. Preuss (2002). Cytotoxicity and oxidative mechanisms of different forms of chromium. *Toxicology*, **180**(1): 5-22.
- Barros, H.R., T.A. Ferreira and M.I. Genovese (2012). Antioxidant capacity and mineral content of pulp and peel from commercial cultivars of citrus from Brazil. *Food Chemistry*, **134**(4): 1892-1898. DOI: 10.1016/j.foodchem.2012.03.090.
- Benavente-García, O. and J. Castillo (2008). Update on uses and properties of citrus flavonoids: new findings in anticancer, cardiovascular and anti-inflammatory activity. *Journal of Agricultural and Food Chemistry*, **56**(15): 6185-6205. doi: 10.1021/jf8006568. Epub 2008 Jul 2.
- Bodduluru, L.N., E.R. Kasala, C.C. Barua, K.C. Karnam, V. Dahiya and M. Ellutla (2015). Antiproliferative and antioxidant potential of hesperetin against benzo (a) pyrene-induced lung carcinogenesis in Swiss albino mice. *Chem. Biol. Interact.*, **242**: 345-52. doi: 10.1016/j.cbi.2015.10.020. Epub 2015 Nov 4.
- Boveris, A., M.G. Repetto, J. Bustamante, A.D. Boveris and L.B. Valdez (2008). The concept of oxidative stress in pathology. In: S. Álvarez, P. Evelson (ed.), *Free Radical Pathophysiology*, 1-17, Transworld Research Network: Kerala, India, ISBN: 978-81-7895-311-3.
- El-Khadragy, M.F., E.M. Al-Olayan and A.E. Abdel Moneim (2014). Neuroprotective Effects of Citrus reticulata in Scopolamine- Induced Dementia Oxidative Stress in Rats, **13**(4): 684-90.
- Fathima, K.A. and K.S. Priyanka (2017). Ameliorative effect of *Embllica officinalis* in potassium dichromate induced toxicity in rats. *European Journal of Pharmaceutical and Medical Research*, **4**(3): 267-274.
- Ferreira, S.S., A.M. Silva and F.M. Nunes (2018). Citrus reticulata Blanco peels as a source of antioxidant and anti-proliferative phenolic compounds. *Industrial Crops and Products*, **111**: 141-148. DOI: 10.1016/j.indcrop.2017.10.009.
- Ghosh, J., J. Das, P. Manna and P.C. Sil (2010). Acetaminophen induced renal injury via oxidative stress and TNF-alpha production: therapeutic potential of arjunolic acid. *Toxicology*, **268**(1-2): 8-18.
- Gorinstein, O. Martin-Belloso, Y.S. Park, R. Haruenkit, A. Lojek, M. Ciz, A. Caspi, I. Libman and S. Trakhtenberg (2001). Comparison of some biochemical characteristics of different citrus fruits. *Food Chem.*, **74**: 309-315.
- Gressner, A.M. (2001). The up-and-down of hepatic stellate cells in tissue injury: apoptosis restores cellular homeostasis. *Gastroenterology*, **120**(5): 1285-1288.
- Ha S.K., H.Y. Park, H. Eom, Y. Kim and I. Choi (2012). Narirutin fraction from citrus peels attenuates LPS-stimulated inflammatory response through inhibition of NF-kappaB and MAPKs activation. *Food Chem. Toxicol.*, **50**(10): 3498-3504. doi: 10.1016/j.fct.2012.07.007. Epub 2012 Jul 17.
- Halliwell, B. and J.M.C. Gutteridge (2007). *Free radicals in biology and medicine*, 4th edn. Oxford University Press, New York.
- Han, M.H., W.S. Lee, J.N. Lu *et al.*, (2012). Citrus aurantium L. exhibits apoptotic effects on U937 human leukemia cells partly through inhibition of Akt," *International Journal of Oncology*, **40**(6): 2090-2096. DOI: 10.3892/ijo.2012.1350.
- Hegazy, R., A. Salama, D. Mansour and A. Hassan (2016). Renoprotective Effect of Lactoferrin against Chromium-Induced Acute Kidney Injury in Rats: Involvement of IL-18 and IGF-1 Inhibition. PLOS ONE DOI:10.1371/journal.pone.0151486 March 18.
- Huang, J., R. Tao, L. Li, K. Ma, L. Xu, G. Ai, X. Fan, Y. Jiao and Q. Ning (2014). Involvement of heat shock protein 47 in Schistosoma japonicum-induced hepatic fibrosis in mice. *Int. J. Parasitol.*, **44**(1): 23-35. doi: 10.1016/j.ijpara.2013.08.009. Epub 2013 Dec 1.
- Jayaprakash, G.K., P.S. Negi, S. Sikder, L.J. Rao and K.K. Sakariah (2000). Antibacterial activity of Citrus reticulata peel extracts. *Z Naturforsch C.*, **55**(11-12): 1030-4.
- Justin, J.S., A. Milton and G. Natesan (2014). Phytochemical evaluation of peel of citrus reticulata blanco using various solvent extracts. *International Journal of Pharmaceutical Sciences and Business Management*, **2**(9): 26-35.
- Kim, E. and K.J. Na (1991). Nephrotoxicity of sodium dichromate depending on the route of administration. *Arch Toxicol.*, **65**(7): 537-541.
- Kuhad, A. and K. Chopra (2009). Attenuation of diabetic nephropathy by tocotrienol: involvement of NF κ B signaling pathway. *Life Sci.*, **84**(9-10): 296-301. doi: 10.1016/j.lfs.2008.12.014.
- Li, B.B., B. Smith and M.M. Hossain (2013). Extraction of phenolics from citrus peels. I. Solvent extraction method. *Purif. Technol.*, **48**(2): 182-188. DOI: 10.1016/j.seppur.2005.07.005.
- Li, S., H. Wang, L. Guo, H. Zhao and C.T. Ho (2014). Chemistry and bioactivity of nobiletin and its metabolites. *J. Funct. Foods*, **6**: 2-10.

- Lushchak, V.I. (2012). Glutathione homeostasis and functions: potential targets for medical interventions. *Journal of Amino Acids*, **1-26**: doi:10.1155/2012/736837.
- Ma, E., Q. Cervera and G.M. Mejia Sánchez (1993). Integrated utilization of orange peel. *Bioresour. Technol.*, **44**: 61-63.
- Mohamed, S.S. and A.M. Fayed (2020). Anti-Obesity Synergistic Effect of Pomegranate Seed Oil (PSO) and Arabic Gum (AG) in Albino Rats. *Int. J. Vet. Sci.*, **9(1)**: 84-89.
- Mojzer, E.B., M.K. Hrcic, M. Škerget, Ž. Knez and U. Bren (2016). Polyphenols: Extraction Methods, Antioxidative Action, Bioavailability and Anticarcinogenic Effects. *Molecules.*, **21(901)**: 2-38. doi:10.3390/molecules21070901.
- Mostafa, F.A., A.A. Salem, S.M. Elaby and N.S. Nail (2016). Protective Activity of Commercial Citrus Peel Extracts against Paracetamol induced Hepato-nephro Toxicity in Rats. *Journal of Chemical. Biological and Physical Sciences*, **6(1)**: 070-083.
- Mylonas, C. and D. Kouretas (1999). Lipid peroxidation and tissue damage. *In Vivo.*, **13(3)**: 295-309.
- Navya, K., G. Phani Kumar, Y. Chandrasekhar and K.R. Anilakumar (2018). Evaluation of Potassium Dichromate ($K_2Cr_2O_7$) - Induced Liver Oxidative Stress and Ameliorative Effect of Picrorhiza kurroa Extract in Wistar Albino Rats. *Biological Trace Element Research*, **184(1)**: 154-164. DOI10.1007/s12011-017-1172-2.
- Nudler, S.I., F.A. Quinteros, E.A. Miler, J.P. Cabilla, S.A. Ronchetti and B.H. Duvilanski (2009). Chromium VI administration induces oxidative stress in hypothalamus and anterior pituitary gland from male rats. *Toxicology Letters*, **185(3)**: 187-19.
- O'Brien, T., J. Xu and S.R. Patierno (2001). Effects of glutathione on chromium-induced DNA crosslinking and DNA polymerase arrest. *Mol. Cell. Biochem.*, **222(1-2)**: 173-182.
- Pechova, A. and L. Pavlata (2007). "Chromium as an essential nutrient: a review," *Veterinarni Medicina.*, **52(1)**: 1-18.
- Salama, A.A.A., B.M. Elsayeh, I. El-Kassaby Ismaiel and S.M. El-Shenawy (2014). Comparative evaluation of protective effects of green tea and lycopene in potassium dichromate-induced acute renal failure in rats. *Journal of Chemical and Pharmaceutical Research*, **6(12)**: 168-177.
- Salama, A.A.A., R.E. Mostafa and E.A. Omara (2016). Ameliorative Effects of Phosphodiesterase (PDE) Inhibitors in Potassium Dichromate Induced Acute Renal Failure in Rats. *Int. J. Pharm. Sci. Rev. Res.*, **36(2)**: 40-46.
- Sergeev, I.N., S. Li, C.T. Ho, N.E. Rawson and S. Dushenkov (2009). Polymethoxyflavones activate Ca²⁺-dependent apoptotic targets in adipocytes. *Journal of Agricultural and Food Chemistry*, **57**: 5771e5776. <http://dx.doi.org/10.1021/jf901071k>.
- Shrivastava, R., R.K. Upreti, P.K. Seth and U.C. Chaturvedi (2002). Effects of chromium on the immune system. *FEMS Immunology and Medical Microbiology*, **34(1)**: 1-7.
- Somasekhar, Reddy K., A. Sudheer, M. Geethavani, B. Pradeep Kumar, K.V.V. Veerabhadrapa, Y. Padmanabha Reddy, J. Raveendra reddy and K. Srinivasu (2015). Protective effect of *Cardiospermum halicacabum* on potassium dichromate induced nephrotoxicity in rats. *Int. J. of Res. in Pharmacology and Pharmacotherapeutics*, **4(4)**: 411-415.
- Son, Y.O., P. Pratheesh Kumar, L. Wang, X. Wang, J. Fan, D.H. Kim, J.Y. Lee, Z. Zhang, J.C. Lee, X. Shi (2013). Reactive oxygen species mediate Cr(VI)-induced carcinogenesis through PI3K/AKT-dependent activation of GSK-3 β / β -catenin signaling. *Toxicol. Applied Pharmacol.*, **271(2)**: 239-248. doi: 10.1016/j.taap.2013.04.036. Epub 2013 May 22.
- Sreeram, K. and T. Ramasami (2003). Sustaining tanning process through conservation, recovery and better utilization of chromium. *Resources, Conservation and Recycling*, **38(3)**: 185-212.
- Stanisic, D., A.F. Costa, W.J. Fávaro, L. Tasic, A.B. Seabra and N. Durán (2018). Anticancer Activities of Hesperidin and Hesperetin In vivo and their Potentiality against Bladder Cancer. *J. Nanomed Nanotechnol.*, **9(5)**: 1-6.
- Strasak, A.M., R.M. Pfeiffer, J. Klenk, W. Hilbe, W. Oberaigner, M. Gregory et al., (2008). Prospective study of the association of gamma-glutamyl transferase with cancer incidence in women. *Int. J. Cancer*, **123(8)**: 1902-1906. doi: 10.1002/ijc.23714.
- Valko, M., C.J. Rhodes, J. Moncol, M. Izakovic and M. Mazur (2006). Free radicals, metals and antioxidants in oxidative stress-induced cancer. *Chem. Biol. Interact.*, **160(1)**: 1-40.
- Weckhuysen, B.M. and R.A. Schoonheydt (1999). Olefin polymerization over supported chromium oxide catalysts. *Catalysis Today*, **51(2)**: 215-221. doi:10.1016/S0920-5861(99)00046-2.
- Yam-Canul, P., Y.I. Chirino, D.J. Sanchez-Gonzalez, C.M. Martinez-Martinez, C. Cruz, C. Villanueva and J. Pedraza-Chaverri (2008). Nordihydroguaiaretic acid attenuates potassium dichromate-induced oxidative stress and nephrotoxicity. *Food Chem. Toxicol.*, **46(3)**: 1089-1096.
- Yang, M., T. Tanaka, Y. Hirose and T. Deguchi (1997). Chemopreventive effects of diosmin and hesperidin on N-butyl-N-(4-hydroxybutyl) nitrosamine-induced urinary-bladder carcinogenesis in male ICR mice. *Int. J. Cancer*, **73(5)**: 719-724.
- Zielinska, M., A. Kostrzewa, E. Ignatowicz and J. Budzianowski (2001). The flavonoids, quercetin and isorhamnetin 3-O-acylglucosides diminish neutrophil oxidative metabolism and lipid peroxidation. *Acta Biochimica Polonica.*, **48(1)**: 183-189.